

# HISTOLOGICAL STUDY ON THE FIBROUS ARCHITECTURE OF KIDNEY AND URETER OF JAPANESE QUAIL (*COTURNIX COTURNIX JAPONICA*)\*

A .R. Sreeranjini <sup>1</sup>, M. P. Iyyangar <sup>2</sup> and D. Pramodkumar <sup>3</sup>

Department of Anatomy  
College of Veterinary Science  
Rajendranagar, Hyderabad -30, Andhra Pradesh, India.

## ABSTRACT

*The present study was conducted on kidneys and ureters of 25 adult Japanese quails using light microscope. The kidney was enveloped by a thin connective tissue capsule that was adherent to sub capsular connective tissue. The capsule contained collagen fibers, fine reticular fibers and sparse elastic fibers along with few fibroblasts. Connective tissue fibers from capsule were not extending into the parenchyma. Cortical interstitium contained delicate reticular fibers. The connective tissue covering of medullary lobules consisted of collagen fibers. The medullary interstitium in the Japanese quail was thin and comprised of collagen and reticular fibers. The sub mucosa of intra renal ureteric branches and ureter in Japanese quail contained collagen, elastic and reticular fibers. Tunica muscularis of ureter contained few elastic fibers among smooth muscle fibers. Tunica adventitia was comprised of loose connective tissue containing collagen and elastic fibers.*

**Keywords:** Histology, Kidney, Ureter, Japanese quail, Fibrous architecture

Japanese quails (*Coturnix coturnix japonica*) have been used as laboratory animals similar to rats and mice. They are reported to be more resistant to common pathogenic chicken diseases like Ranikhet disease, Coccidiosis etc. They have shorter generation interval and they yield quick return on low investment. Kidneys play an important role in maintaining homeostasis. A bird with no kidney function is reported to die within 36 hours (Dhawale

and Phatak, 1998). Scanty information is available on the fibrous architecture of kidney and ureter of Japanese quail. Hence the present study was undertaken.

25 adult Japanese quails of 7-8 weeks of age were collected from Department of Poultry Science, CVSc, Rajendranagar and kidneys and ureters were collected immediately after humanely

---

\*Part of MVSc Thesis submitted to Sri Venkateswara Veterinary University, Tirupati (formerly under ANGR Agricultural University, Rajendranagar, Hyderabad 500 030).

Present address: <sup>1</sup>Assistant Professor, Department of Veterinary Anatomy and Histology, College of Veterinary and Animal Sciences, Pookot, Wayanad, Kerala. <sup>2</sup> Professor and University Head (Retd.), (Plot No: 236, House No: 5-11-279, Sri Venkateswara Nagar Colony, Meerpet, Hyderabad-40). <sup>3</sup> Associate Professor and Head, Department of Anatomy, College of Veterinary Science, Rajendranagar, Hyderabad-30

sacrificing them. Fresh tissue pieces were fixed in various fixatives like 10% Neutral Buffered Formalin, Bouin's solution and Zenker's solution. Fixed tissue pieces were then processed for routine histological studies. 5-7  $\mu$ m thick paraffin sections were stained by Mayer's Haemalum - Eosin-Phloxine method (Singh and Sulochana, 1996), Van-Gieson's method (Singh and Sulochana, 1996), Weigert's method for elastic fibers (Luna, 1968), Wilder's method for reticulum (Luna, 1968) and Crossman's modification of Mallory's triple stain method (Singh and Sulochana, 1996).

**Kidney:**

In the present study, kidneys were covered by a thin connective tissue capsule that was adherent to sub capsular connective tissue. This finding was in agreement with that of Fitzgerald (1969) in coturnix quail. The capsule in the current study contained collagen fibers, fine reticular fibers and sparse reticular fibers along with few fibroblasts (Fig.1). Connective tissue fibers were not extending

into the parenchyma to divide it into lobules. Contrary to this, Fitzgerald (1969) observed inter lobular connective tissue and distinct lobulation in coturnix quail. Sub capsular venous sinuses containing red blood corpuscles could be seen in the present study.

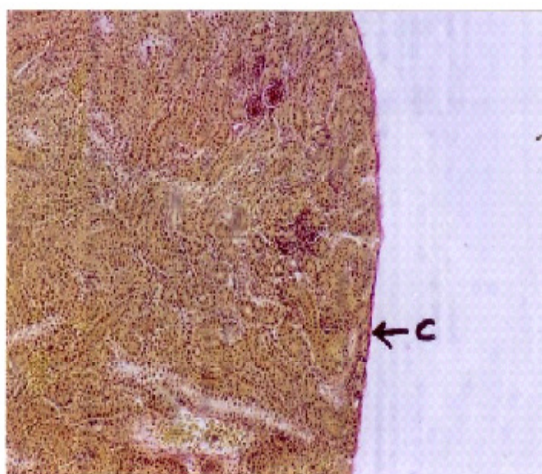
Delicate reticular fibers were observed surrounding and supporting the renal tubules and blood vessels in the cortex, similar to the findings of Fitzgerald (1969) in coturnix quail. The glomerular mesangium was supported by collagen and reticular fibers. The connective tissue covering of medullary lobules and the medullary interstitium in Japanese quail was thin and This was in agreement with the observations of Siller (1971) who reported that medullary interstitium in fowl was rich in reticular and collagen fibers.

**Ureter:**

The sub mucosa of intra renal ureteric branches and ureter in Japanese quail contained

**Fig.1:**

**Photomicrograph of kidney of Japanese quail showing thin capsule containing collagen fibres. Van - Gieson's method. X 32. C - Capsule containing collagen fibres**



Photomicrograph of kidney of Japanese quail showing reticular fibres in medullary interstitium. Wilder's reticulum. X50. RF - Reticular fibres

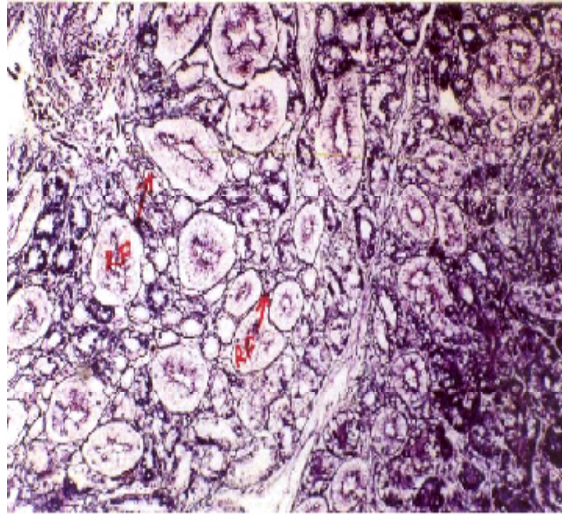
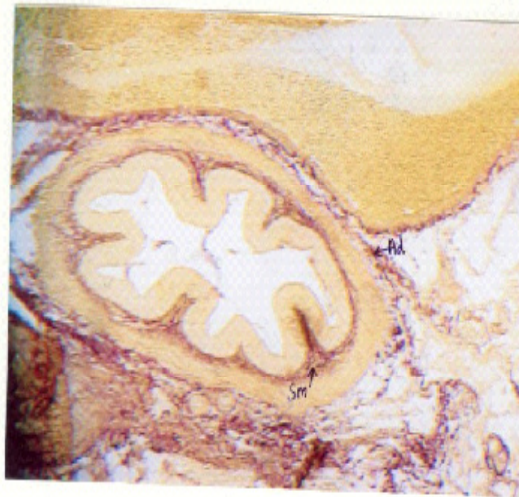


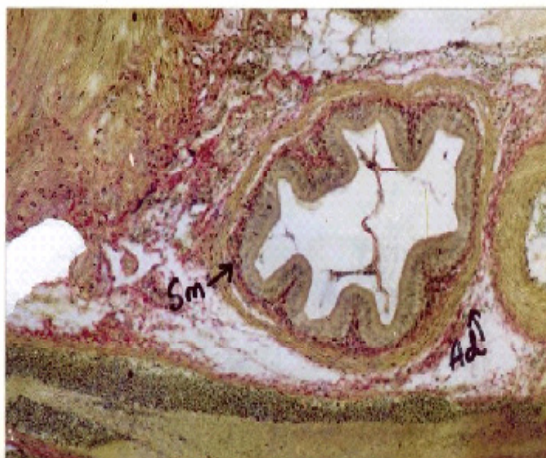
Fig.3:

Photomicrograph of ureter of Japanese quail showing collagen fibres in sub mucosa and adventitia. Van - Gieson's method. X 32. Sm -Sub mucosa, Ad-Adventitia



**Fig.4:**

**Photomicrograph of ureter of Japanese quail showing elastic fibres in sub mucosa and adventitia. Weigert's method for elastic fibers. X 32. Sm -Sub mucosa, Ad-Adventitia**



collagen, elastic and reticular

Contrary to this, Hodges (1974) has reported the presence of a thick layer of sub epithelial loose connective tissue with well developed elastic fiber network in the ureter of fowl. Liu (1962) observed thick lamina propria with elastic network in duck. In Japanese quail, tunica muscularis of ureter contained few elastic fibers among smooth muscle fibers. Tunica adventitia comprised of loose connective tissue containing collagen and elastic fibers.

#### REFERENCES

Dhawale, A. and Phatak, R. (1998). Visceral gout - a matter of cracking the crystals. *World Poultry*, 14: comprised of collagen and reticular fibers (Fig.2). 85-87.

Fitzgerald, T. C. (1969). Urinary Organs. In: *The Coturnix Quail, Anatomy and Histology*. 1<sup>st</sup> ed. The Iowa State University Press, Ames, Iowa. pp. 253-255

Hodges, R. D. (1974). The Urinary system. In: *The Histology of the Fowl*. Academic Press, London, New York, San Francisco. pp. 489-524.

Liu, H.C. (1962). The comparative structure of the ureter. *American Journal of Anatomy*, 111:1-15.

Luna, L.G. (1968). *Manual of histological staining methods of the Armed Forces Institute of Pathology*. 3<sup>rd</sup> ed. Mc Graw - Hill Book Company, New York.

Siller, W. G. (1971). Structure of the kidney. In: Bell D J and Freeman BM (Ed) *Physiology and Biochemistry of the Domestic Fowl*. Vol.1. Academic Press, London, New York. pp. 197-231

Singh, U.B. and Sulochana, S. (1996). *Handbook of Histological and Histochemical Techniques*. 2<sup>nd</sup> ed. 5 -1-800, Kothi, Hyderabad, Andhra Pradesh, India. Premier Publishing House.