

# MAREK'S DISEASE AND LYMPHOID LEUCOSIS IN CHICKEN – A HISTOPATHOLOGICAL SURVEY

**C.Balachandran, N.Pazhanivel, S.Vairamuthu and B.Murali Manohar**

Department of Veterinary Pathology  
Madras Veterinary College  
Chennai-600 007

**Key words:** Marek's disease, lymphoid leucosis, histopathological survey

Marek's disease (MD) is a lymphoproliferative disease of chicken caused by cell associated MD herpes virus (MDV) and is characterized by multiple T-cell lymphoma formation in visceral organs, muscles, skin and lesions in peripheral nerves (Calnek and Witter, 1991). Clinical signs observed for MD vary from mild depression followed by ataxia and paralysis, skin nodular lesions, stunting and mortality (Santin *et al.*, 2006). The avian leucosis virus induces a well studied lymphoma in chicken called lymphoid leucosis (Pizer and Humpheries, 1989).

The present paper describes a histopathological survey of Marek's disease and lymphoid leucosis in chicken tissue samples.

A total of 767 tissue samples were received from different parts of India and Bangladesh during the period from July 2006 to June 2007 for histopathological examination. The tissue samples were processed by routine paraffin embedding and 4 to 6 mm sections were stained with haematoxylin and eosin stain by employing standard procedures. Out of 767 tissue samples, 99 tissue samples (12.91%) were diagnosed as Marek's disease and 15 samples (1.96%) as lymphoid leucosis on the basis of presence of homogenous lymphoid cell infiltration in lymphoid leucosis and pleomorphic lymphoid cell infiltration with MD cells and peripheral nerve showing neoplastic lymphoid cell infiltration in Marek's disease.

Out of 767 tissues, 73 tissues were from broiler chicken and 694 from layer chicken. From the above tissues, five tissues (6.85%) from broilers and 94 tissues (13.54%) from layers had lesions suggestive of Marek's disease. Marek's disease involved the liver (34.34% - Fig. 1), spleen (26.26%), kidneys (12.12%), ovaries (7.07% - Fig. 2), proventriculus (8.08%), lung (4.04%), sciatic nerve (3.03% - Fig. 3), intestine (2.02%), skin (1.01%) and mesentery (1.01%). The sciatic nerves revealed infiltration of proliferating lymphoblasts, large, medium and small lymphocytes suggesting type A lesion (OIE, 2004). Panneerselvam *et al.* (1990) reported lesions of Marek's disease in the liver, spleen, kidney, proventriculus, ovary, nerve, heart and lungs of layers. In the present study, lesions suggestive of Marek's disease has been recorded in the above mentioned organs except the heart and also in the intestine, mesentery and skin.

In the present survey, MD has been recorded from 6 to 50 weeks of age. Panneerselvam *et al.* (1990) reported that the percentage of mortality due to Marek's disease was higher in the younger age group (9-20 weeks) than that of older birds (above 20 weeks) and peak mortality was encountered between 16-26 weeks of age. Panda *et al.* (1983) reported that higher mortality was due to Marek's disease during 21-40 weeks of age and lower mortality rate in 9-20 weeks. The disease starts as a proliferation of lymphoid cells which is progressive in some cases and regressive

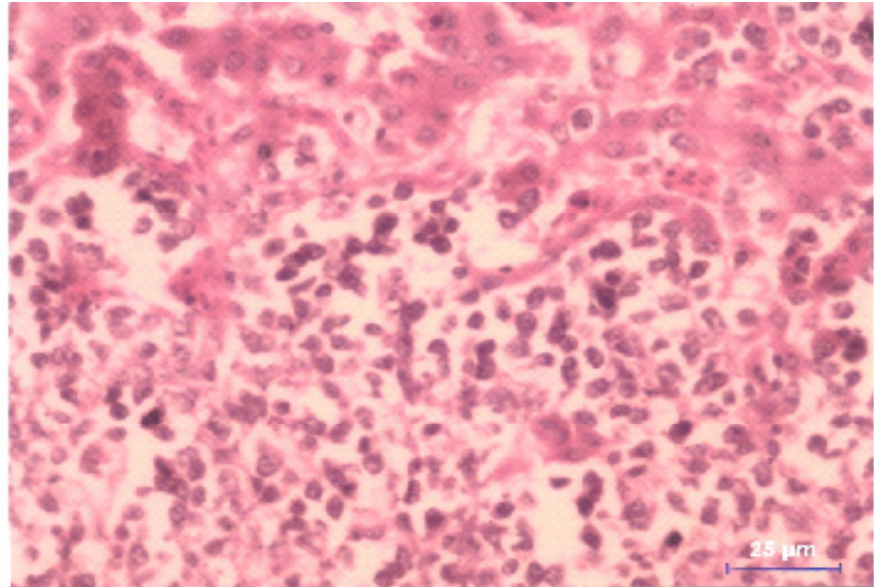
in others (OIE, 2004). Occurrence of MD in adult commercial type chickens might be due to *de novo* infection (Super infection) with highly virulent strains despite existing levels of vaccine immunity and age resistance (Witter, 2001) which is in agreement with the present findings where in all layer type chicken were vaccinated against Marek's disease.

Lesions suggestive of lymphoid leucosis was observed in 15 tissues (2.16%) of layer birds. The lymphoid leucosis involved liver (26.67% - Fig. 4) and spleen (73.33%) tissues. However, lymphoid leucosis was not recorded in any of the tissues from broiler birds. In the present study, lymphoid leucosis was mostly recorded in birds over 13 weeks of age and is in agreement with an earlier report (Darcell, 1994).

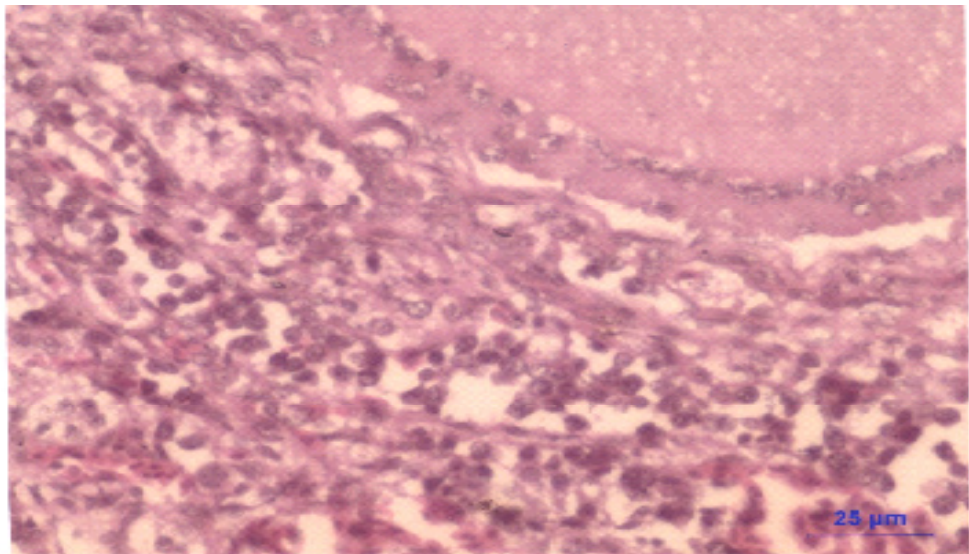
#### REFERENCES

- Calnek, B.W. and Witter, R.L. (1991). Marek's disease. In: Diseases of Poultry. Eds. Calnek, B.W., Barnes, H.J., Beard, C.W., Reid, W.M. and Yoder Jrs, H.W. 9<sup>th</sup> Edn. Iowa state University Press, Ames, Iowa, pp: 342-385.
- Darcell, C. (1994). Reflections on the pathogenesis of diseases caused by the acute avian leucosis/sarcoma viruses with special reference to avian erythroblastosis. *Vet.Res.Com.*, **18**: 397-415.
- Office International des- Epizooties (OIE). (2004). Marek's disease. In: Manual of Standards for Diagnostic Tests and Vaccines. OIE Terrestrial Manual. 5<sup>th</sup> Edn., Rome.
- Panda, B.K., Arya, S.C., Pradhan, H.K. and Johri, D.C. (1983). Marek's disease in chicken in various strains of White Leghorn. *Indian J. Poult. Sci.*, **18**: 100.
- Panneerselvam, S., Dorairajan, N., Balachandran, C. and Murali Manohar, B. (1990). Incidence of Marek's disease in Namakkal, Tamil Nadu. *Cheiron*, **19**: 143-144.
- Pizer, E. and Humphries, E.C. (1989). RAV-1 insertional mutagenesis: Disruption of the c-myc locus and development of avian B-cell lymphomas. *J. Virol.*, **63**: 1630-1640.
- Santin, E.R., Shamblin, C.E., Pigge, J.T., Arumugaswami, V., Dienglewicz, R.L. and Parcels, M.S. (2006). Examination of naturally occurring mutation in glycoprotein L on Marek's disease virus pathogenesis. *Avian Dis.*, **80**: 96-103.
- Witter, R.L. (2001). Protective efficacy of Marek's disease in vaccines. In: Current Topics in Microbiology and Immunology. Hirai, K. Ed. SpringerVerlag, Berlin. pp. 58-90.

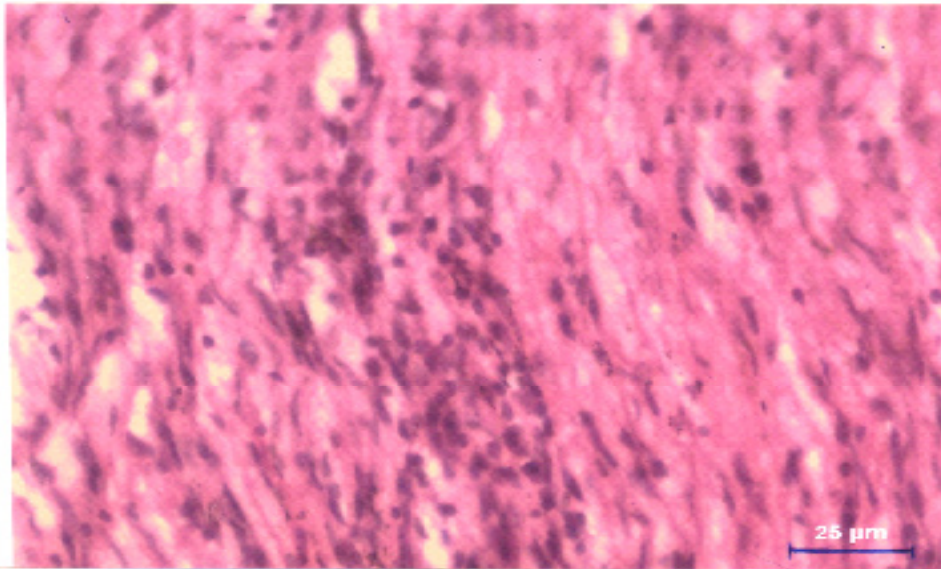
**Fig.1. Marek's disease – Liver- Pleomorphic lymphoid cell infiltration. H&E Scale bar 20 mm**



**Fig.2. Marek's disease – Ovary - Pleomorphic lymphoid cell infiltration H&E Scale bar 20 mm**



**Fig.3. Marek's disease – Sciatic nerve - Pleomorphic lymphoid cell infiltration H&E Scale bar 20 mm**



**Fig.4. Lymphoid leucosis – Liver- Multifocal uniform sized lymphoid cell infiltration H&E Scale bar 20 mm**

